INFECTION RATES IN BONE FLAP CRANIOPLASTY – AN INSTITUTIONAL EXPERIENCE

Original Research Article

ISSN : 2456-1045 (Online)
(ICV-MDS/Impact Value): 63.78
(GIF) Impact Factor: 4.126
Publishing Copyright @ International Journal Foundation
Journal Code: ARJMD/MDS/V-26.0/I-1/C-3/JN-2018
Category : MEDICAL SCIENCE
Volume : 26.0 / **Chapter-** III / **Issue** -1 (JUNE-2018)
Journal Website: www.journalresearchijf.com
Paper Received: 05.06.2018
Paper Accepted: 11.06.2018
Date of Publication: 05-07-2018
Page: 08-10

Name of the Author (s):

Dr. Sibhi Ganapathy [1*], Dr. Rajesh Nair [2], Dr. Vinod Kumar [3]

[1]*MBBS, MS, Mch, DNB, FAGE, Consultant Neurosurgeon, Manipal Hospital Whitefield, Bangalore, Karnataka , India*

[2]*MBBS, MS, Mch, Assistant Professor, Department of Neurosurgery, Kasturba Medical College, Manipal University, Manipal, Karnataka , India*

[3]*MBBS, MS, Mch, Professor and Head, Neurosurgery Unit 2, Department of Neurosurgery, Kasturba Medical College, Manipal University, Manipal, Karnataka , India*

Citation of the Article

Ganapathy S ; Nair R ; Kumar V; (2018) *Infection rates in Bone Flap Cranioplasty – An Institutional Experience. ; Advance Research Journal of Multidisciplinary Discoveries.26(3)pp. 08-10*

ABSTRACT

Large bone flap decompressive craniectomies have a varied application in modern day neurosurgery. They may be used to combat malignant cerebral edema secondary to trauma, hypoxia or toxic encephalopathies. After the edema subsides, the process of replacing the removed bone flap or bridging the defect of the calvarium with synthetic compounds has assumed great significance, especially over the last decade where cosmesis and quality of life have assumed great importance.

Apart from just fixing the bone flap back onto the calvarial defect once the edema has subsided, a variety of synthetic materials have been created to optimize the fit, stability and cosmesis of the procedure.

A major concern of cranioplasty is post-operative infection. The incidence of which is rising to almost 30% of all cases as reported by. The propensity of the bone flap to get infected is greater due to the devitalized nature of the dead bone fragment used for mechanical closure. Foreign materials such as bone cement, metal meshes or acrylic are also susceptible to carry infection if improperly handled or sterilized. These infections can lead to failure of the procedure and eventual loss of the bone flap to life threatening infections and meningitis.

Hence, proper asepsis is the key to ensure a proper and favorable result. We present our experience of 3 years of cranioplasty done at a tertiary care center.

I. INTRODUCTION

Decompressive Craniectomy is widely practiced in neurosurgery to manage Intractable ICP in traumatic brain injury, aneurysmal SAH, tumor related oedema or ischemic stroke. [1,2] Once the oedema subsides, the filling of the calvarial defect with either the original bone flap or a synthetic substitute becomes a priority. The needs of cosmesis as well as mechanical protection of the delicate intracranial contents from blunt and penetrating trauma require a substance to mimic the consistency, as well as contours of the natural calvarial bone. [2,3]

Cranioplasty has been present for a while with replacement of the removed bone flap being conducted since ancient times. The advent of titanium meshes and a variety of bone substitutes have improved the cosmetic aspects of cranioplasty while retaining the structural mechanical protection function.

Cranioplasty can hence be classified as:

- Autologous Bone

The most popular construct in use. This is of 2 types. The bone flap once removed is either placed in a **supra-peritoneal pouch** or kept autoclaved and cleaned in the hospital **bone bank** for future use. The advantages include usage of the same bone, better contour for the calvarium, and a cheaper cost of procedure. As the bone is denatured, it can be susceptible for infection.

- Allologous Bone (not performed anymore)
- Xenologous Bone (Not performed due to ethical reasons)
- Artificial substitutes:
  - Titanium meshes
  - PMME Bone cement
  - Combination constructs
  - Polymer constructs (made to the exact mold of the defect and fitted on.

The prosthetic substances either replace or complement existing bone flap. The resulting constructs are strong and cosmetically acceptable, but are susceptible to infections and are expensive. [3]

The main concern in cranioplasty is the susceptibility of the replacement construct to infection. Various sources place the incidence of post cranioplasty infection between 20-30%. [3,4] These infections range from trivial stitch abscesses to life threatening empyema with septicemia. The association of infection with a particular construct has not been clearly studied nor has an association been between bone flap maintenance been established. Nevertheless, aseptic practices combined with the best cosmetic techniques allow acceptable results.

We present our experience of cranioplasty in a high volume specialized tertiary care center which deals with economically disadvantaged patients in addition to paying patients.

II. MATERIALS AND METHODS

All patient undergoing Cranioplasty, irrespective of the type of material used were included in the study for a period of 3 years in the department of Neurosurgery, Kasturba Medical College and Hospital Manipal India. The patients were then followed up after discharge for 1 year and examined for infection rates, bone flap/prosthesis removal or other complications associated with the bone flap. These were tabulated and analyzed with respect to infection rates, readmissions and overall cosmesis.

III. RESULTS

From April 2014 to July 2016, 54 cranioplasties were performed in the department of neurosurgery KMC Manipal.

Of these 44 were males and 10 were females.

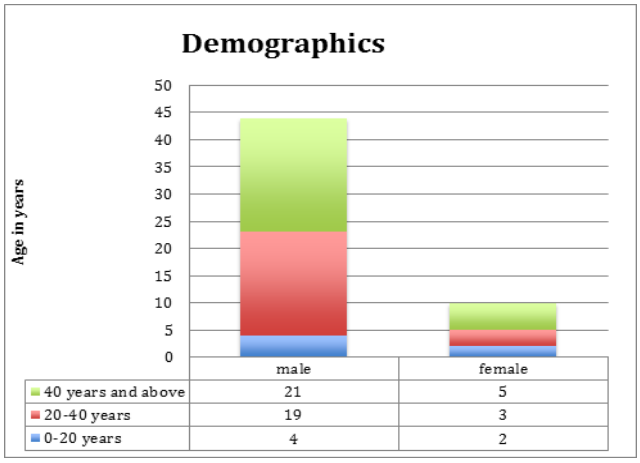

Fig-1

The commonest material used for the procedure was the autologous bone flap. All or bone flaps were stored in abdominal pouches and were retrieved at the same time as the replacement procedure. In depressed or fractured crania, the bone fragments were pieced together with mini-plates or nylon thread and replaced over the defect.

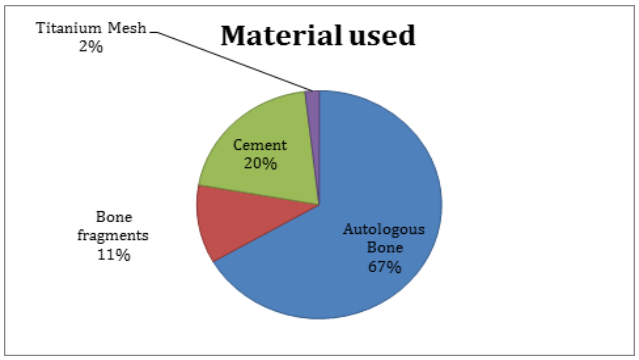

Fig-2

In cases where the calvarium was merely damaged with no intracranial oedema, immediate replacement of the bone flap was effected after repair. Else the commonest time period between decompression and cranioplasty was 4-6 weeks, which is in line with the international norms.

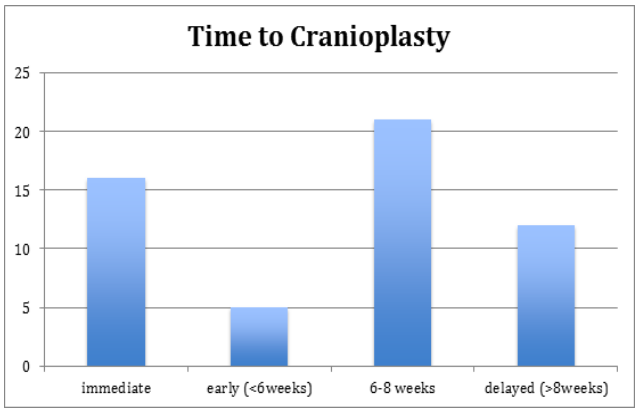

Fig-3

Most of the patients were of traumatic brain injury where subdural hematomas were the most common presentation. Infarcts were most commonly done for MCA infarcts. Rarer causes include craniosynostosis cranioplasty procedures (for 2 children) as well as calvarial bony tumor excision where the involved bone required excision as well.

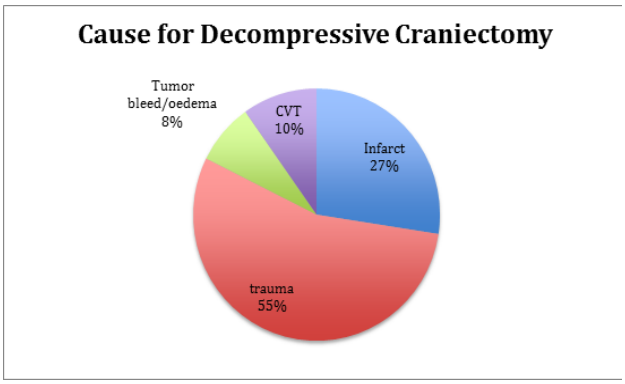

Fig-4

The **incidence of infection** was only **6 in all the 54 cases (11.1%)**, which is significantly lower than the published data available. The infected cases were more in cement cranioplasties as shown below as well as in traumatic fractures where there was already a source of infection secondary to contamination of the wound from an open head injury.

DISEASE TYPE	INCIDENCE OF INFECTION	TYPE OF CONSTRUCT
TRAUMA	5 (83.33%)	2 bone 3 cement
CVT	0	0
INFARCT	0	0
TUMOR	1 (16.67)	1 cement
TRAUMA TYPE	**INCIDENCE OF INFECTION**	**TYPE OF CONSTRCUT**
Open FRACTURES	4(80%)	3 cement 1 bone
ICH	0	0
EDH	0	0
SDH & Contusions	1 (20%)	1 bone

IV. DISCUSSION:

With the incidence of strokes and head trauma on the rise, there is an increasing urgency into defining the requirements for decompressive Craniectomy as well as cranioplasty. Patients have become increasingly cosmetically conscious, implying that the techniques of old cannot be sustained without effecting changes in technique and approach.

Despite the advances in cosmesis, the essential problems of the cranioplasty remain – that a devitalized piece of bone or a foreign body are being placed onto an extremely vulnerable and damaged brain, and hence, the complications that ensure are major. [(1)] Bone flap infections with empyema as well as flap necrosis remain important issues irrespective of the type of procedure done. [(1,2)] The importance of strict asepsis while performing this procedure cannot be emphasized enough. Despite precautions cranioplasty infections remain high (as high as 20-30%). [(1,2,3)] Reducing this incidence has become a matter of urgency.

Our data collected over 3 years show a low incidence of infection irrespective of the material used. Infection rates are lower for autologous bone cranioplasties probably because all bone flaps were stored in the abdominal pouch from the time of decompression and ere only removed at the time of replacement. The sterile conditions of the pre-peritoneal placement can possibly contribute to the higher rate of acceptance.

Although our experience in molds produced by3D printing is minimal this is an increasingly popular method of bone flap replacement where the reconstruction is done exactly as per the defect of the bone. [(3)] The molds add another fomite that can be susceptible for infection. Hence extra care needs to be taken while executing a procedure of this nature.

Cranioplasties in a financially stringent situation can be a challenge, especially as complications can severely retard the patient's medical and financial status. [(3,4,5)] A judicious approach to surgery, abdominal pouches for autologous bone flap replacements, and strict asepsis can minimize these complications as well as present a low cost yet highly effective method of cranioplasty for the masses, especially in the developing world.

V. CONCLUSION

Cranioplasties, when done in proper asepsis for the right indications are a highly satisfying procedure for both patient and doctor alike. The avoidance of infection remains a challenge that can be faced by maintaining exacting standards of sterility as well as preferring an abdominal pouch contained autologous bone flap replacement techniques where flap handling is kept to the minimum. Such a technique is also financially viable in a developing Country such as India.

REFERENCES

[1]. **Aziz TZ, Mathew BG, Kirkpatrick PJ:** Bone flap replacement versus acrylic cranioplasty: a clinical audit. Br J Neurosurg 1990; 4:417-419

[2]. **Bullock MR, Chestnut RM, Clifton G, Ghajar RP, Young HF, Marion DW, et al:** Management and prognosis of severe traumatic brain injury. Part I: Guidelines for the management of severe traumatic brain injury. J Neurotrauma 2000; 17: 449-453

[3]. **Chang V, Hartzfeld P, Langlois M, Mahmood A, Seyfried D:** Outcomes of cranial repair after craniectomy. J Neurosurg 2010; 112:120-124

[4]. **Chiang H, Steelman V, Pottinger J, Schlueter A, Diekema D, Greenlee J, et al:** Clinical significance of positive cranial bone flap cultures and associated risk of surgical site infection after craniotomies or craniectomies. J Neurosurg 2011; 114:1746-1754 \

[5]. **Cooper D, Rosenfeld J, Murray L, Arabi YM, Davies AR, D'Urso P, et al**: Decompressive craniectomy in diffuse traumatic brain injury. N Engl J Med 2011; 364:1493-1502

*****

Corresponding author :

Dr. Sibhi Ganapathy *
MBBS, MS, Mch, DNB, MNAMS, FRCS, FAGE
Manipal Hospital Whitefield, Bengaluru 560066
Email : sibhig [at]yahoo.co.uk