Anatomy of Suprascapular Notch (SSN), Suprascapular Nerve Entrapment and its Clinical Significance.

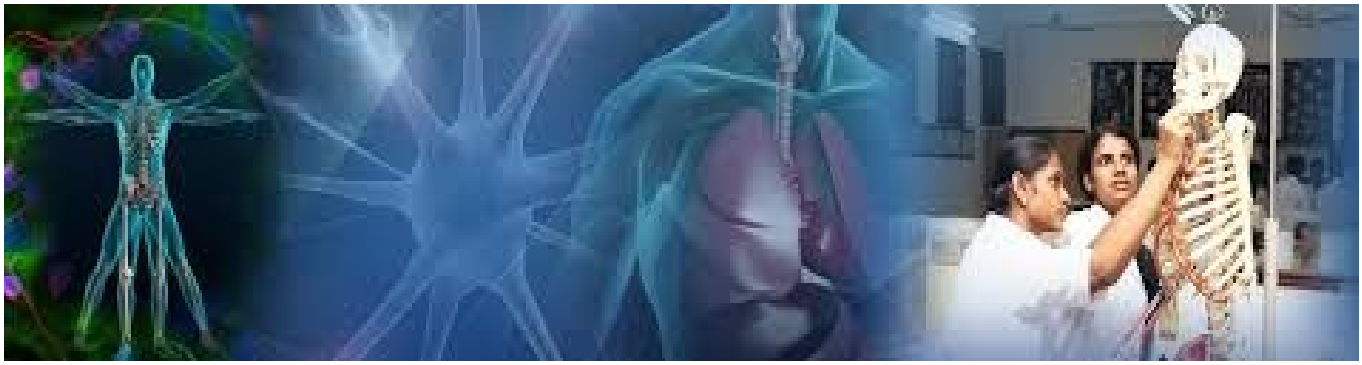

Original Research Article

ISSN : 2456-1045 (Online)
(ICV-MDS/Impact Value): 63.78
(GIF) Impact Factor: 4.126
Publishing Copyright @ International Journal Foundation
Journal Code: ARJMD/MDS/V-25.0/I-1/C-2/MAY-2018
Category : MEDICAL SCIENCE
Volume : 25.0 / **Chapter-** II / **Issue** -1 (MAY-2018)
Journal Website: www.journalresearchijf.com
Paper Received: 27.04.2018
Paper Accepted: 03.05.2018
Date of Publication: 10-06-2018
Page: 12-15

Name of the Author (s):

Dr. Shabana Sultana [1]
Dr. Mrudula Chandrupatla [2]

[1]*Tutor, Department of Anatomy, Apollo Institute of Medical Sciences and Research, Hyderabad, Telangana, India.*

[2] *Professor & HOD, Department of Anatomy, Apollo Institute of Medical Sciences and Research, Hyderabad, Telangana, India.*

Citation of the Article

Sultana S. ; Chandrupatla M. (2018) *Anatomy of Suprascapular Notch (SSN), Suprascapular nerve entrapment , and its clinical significance.; Advance Research Journal of Multidisciplinary Discoveries.25(2)pp. 12-15*

ABSTRACT

The suprascapular notch is located on the lateral part of the superior border of the scapula, medial to the coracoid process. It is covered by the superior transverse scapular ligament which gives passage to suprascapular nerve to supraspinous fossa. Suprascapular nerve entrapment may occur due to the different morphology of the suprascapular notch or due to ossification of the superior transverse scapular ligament. The suprascapular nerve passes through several osseoligamentous structures and can be compressed in several locations. Morphometric studies of suprascapular notch have been done in various studies. The aim of the present study is to review the morphometric studies of suprascapular notch, identify the most common type of notch. The suprascapular notch (SSN) is important, as it is major risk factor for suprascapular nerve entrapment syndrome. The study was conducted at Apollo Institute of Medical Sciences,Hyderabad,Telangana State,India. Fifty scapulae were used for the study of the suprascapular notch anatomy which may help to prevent and to assess more accurately suprascapular nerve entrapment syndrome.

KEYWORDS :

Suprascapular notch, Suprascapular nerve, Suprascapular nerve entrapment, Scapula Anatomic classification

I. MATERIALS AND METHODS

The study was conducted at Apollo Institute of Medical Sciences, Hyderabad,Telangana State,India. Fifty scapulae were used. Suprascapular nerve which supplies motor branches to the supraspinatus, infraspinatus, and sensory branches to the rotator cuff muscles, and the ligamentous structures of the shoulder and acromioclavicular joint. The anatomical variation of the SSN, which includes the variation in shape, complete or partial ossification of the STSL, is recognized as one of the causes of suprascapular nerve entrapment.In 1952 the German neurologist E.Schilf first described unilateral shoulder paralysis due to the compression of the suprascapular nerve [1],which was further confirmed by Kopell and Thompson [2] in 1959.Suprascapular nerve pathology Is one of the causes of shoulder pain and weakness as SSN has to pass through narrow formen between osseoligamentous structures.. The suprascapular notch (SSN) variations are usually responsible for suprascapular nerve entrapment syndrome. The purpose of this study is to describe the morphology of the SSN of a sample of normal scapulae in the Apollo Institute of Medical Sciences,Hyderabad,Telangana State, India. Fifty scapulae were used. The superior transverse diameter and maximal depth of the notches were measured. The Rengachary classification method was adopted to describe the shape of the SSN. Analysis of morphological variations showed Type III- U-shaped notch to be predominant (46%). Three scapulae had absent notches (Type I) (6%). The average notch depth and transverse diameter were 5.96±1.98 mm and 12.94±5.02 mm respectively. The right SSN were significantly deeper than the left (6.86±2.06 mm) (p2012; Kannan et al.). The most widely used classification method by Rengachary et al. (1979). The Rengachary method classifies the SSN into six categories based on its shape: Type I,where notch is absent; Type II, a wide and blunt v-shaped notch; Type III, a symmetrical u-shaped notch; Type IV, a small, v-shaped notch; Type V,where notch is minimal and U shaped and Type VI, with the ligament completely ossified forming a foramen. These studies conclude that a supra scapular nerve entrapment is more common with smaller notch. (Kannan et al.). It has been accepted that suprascapular nerve entrapment occurs commonly in narrow 'V' shaped notch. clinically it has not been proved that suprascapular nerve entrapment is associated with shape of suprascapular notch(Soni et al., 2012). Numerous studies on Caucasian subjects especially in Europe and Asia have shown that the Type III (U-shape) notch was the most prevalent shape (Sinkeet et al.; Polguj et al., 2011; Iqbal & Iqbal; Sangam et al.; Vasudha et al., 2013; Albino et al., 2013). In addition, only few studies have been conducted in the African population (viz Kenya and Nigeria) with no studies describing the morphology of the SSN within the South African population. Recent studies have modified Rengachary et al. classification, suggesting that relating the dimensions of the SSN to shape may yield a more precise catergorization (Polguj et al., 2013). A study by Yücesoy et al. illustrated through using ultrasound that the SSN depth was significantly higher in males than in females, and that there was no significant difference for the notch width between the two sexes. A similar study carried out by Polguj et al. (2013) reported that there is a positive correlation between morphological length of the scapula and maximum depth of the notch. Whilst Albino et al. concluded that gender, age and scapular dimensions are not related to the dimensions and type of suprascapular notch. Although these classification methods may seem to be more specific when compared with Rengachary's classification they are still quite new, and literature suggest that further investigationsis required. The three most commonly used classifications used by various workers are those proposed by Rengachary et al [6], Natsis et al [2] and Ticker et al [7].The aim of this study therefore, was to describe and compare the morphology and morphometry of the SSN within a Indian population using normal dried osteological cadaveric scapulae comparing it to maximal width and length of the scapulae, laterality and sex.The data was analysed using the SPSS version 22.0 (SPSS Inc., Chicago Illinois, USA).

II. AIM AND OBJECTIVES

Literature review was done using online data which will define the pathophysiology and guides diagnosis and treatment of Suprascapular nerve entrapment.The aim of the present study is to review the morphometric studies of suprascapular notch, identify the most common type of notch and compare it in different populations. The articles included in this review were based on the morphometric studies of suprascapular notch in various populations and the articles with more number of citations were included.

III. DISCUSSION

The knowledge of SSN is important in the treatment of suprascapular nerve entrapment. There is limited data on the morphology of the SSN in relation to gender, laterality or scapular dimensions within the Indian population. The Type III Notch is U-shaped and was found in 48% of the sample population (Normal Indian population 35% (Vandana & Patil, 2013).This indicates that the chances of nerve impingement/ entrapment would be less. the incidence of the Type III in the Kenyan population was 29% (Sinkeet et al.), and Polish population 56.16% (Polguj et al., 2011). Whilst Albino et al., noted that Type IV (V- shaped) notch was more prevalent in the Italian population (31.1%). Odita et al. (1983) indicated that the shape of the SSN is influenced by the ossification of coracoid process which occurred earlier in the Nigerian population compared to Caucasians, thereby explaining differences between populations and SSN morphology. The incidence of complete ossification of the superior transverse scapular ligament (STSL) varies between different populations from 3.7 to 13.6% as shown in the literature (Polguj et al., 2011). Partial or complete ossification has been identified to be one of the predisposing factors in cases of suprascapular nerve entrapment (Soni et al.). The present study observed that in Type I (6%): Suprascapular Notch is absent. Type II (10%): Suprascapular Notch is a blunted V-shape.Type III (46%): Suprascapular Notch is U-shaped.Type IV (2%): Suprascapular Notch is V-shaped and very small.Type V (32%): Suprascapular Notch is minimal and U-shaped .Type VI (4%): Suprascapular Notch is a foramen .All these types may cause suprascapular nerve entrapment (Sinkeet et al.; Polguj et al., 2011; Soni et al.). In this study, the shapes of the SSN were . This implies that the depth of the suprascapular notch was significantly related to the laterality of the scapula making the site for suprascapular nerve entrapment susceptible to this trend. The dimensions of the scapular (i.e. length of scapular and width of scapular) were significantly larger in males. The notch depth was larger in males, where as the superior transverse diameter was wider in females. This finding is similar to an ultrasonographic study conducted by Yücesoy et al. but differs to Polguj et al. (2013) which noted that all dimensions are higher in males. Whilst, Albino et al. noted that gender did not influence the type of SSN morphology. The study was performed with a limited number of dried cadaveric scapulae. Further research is needed to confirm the correlation between notch type and suprascapular nerve entrapment utilizing other sources such as radiographic images as well as a larger sample size.

Shape of Suprascapular Notch	No. of Scapulae	Percentage (%)
Type I (8%): Notch is absent	3	6%
Type II (31%): Notch is a blunted V-shape	5	10%
Type III (48%): Notch is U-shaped	23	46%
Type IV (3%): Notch is V-shaped and very small.	1	2%
Type V (6%): Notch is minimal and U-shaped.	16	32%
Type VI (4%): Notch is a foramen	2	4%

IV. SHAPES OF SUPRASCAPULAR NOTCH

TYPE-I

TYPE-II

TYPE-III

TYPE-IV

TYPE-V

TYPE-VI

Anatomical Variations Of The Suprascapular Notch Are Important As Possible Predisposing Factors For Compression Of The Suprascapular Nerve In This Region, Especially In People With Violent Overhead Activities, Such As Volleyball Players And Baseball Pitchers [8,9]. The Knowledge Of Variations Of The Shape Of SSN And Incidence Of Ossification Of STSL Is Also Essential In Various Techniques Associated With Arthroscopic SN Decompression [10-12]. The Analysis Of The Literature Revealed That Various Authors Have Used Mainly Three Different Classifications To Study The Morphometry Of Suprascapular Notch. Rengachary Et Al [6] Observed Six Basic Types Of Supracapular Notch In 211 Cadaveric Adult Scapulae: Type I (No Notch): The Entire Superior Border Of The Scapula Showed A Wide Depression From The Medial Superior Angle Of The Scapula To The Base Of The Coracoid Process (8%). Type II: This Type Showed A Wide, Blunted 'V'-Shaped Notch Occupying Nearly A Third Of The Superior Border Of The Scapula. The Widest Point In The Notch Was Along The Superior Border Of The Scapula (31%). Type III: The Notch Was Symmetrical And 'U'shaped With Nearly Parallel Lateral Margins. Type IV: The Notch Was Very Small And 'V'shaped. Frequently A Shallow Groove Representing The Bony Impression By The Suprascapular Nerve Was Visible Adjacent To The Notch (3%). Type V: This Type Was Very Similar To Type III ('U' Shaped), With Partial Ossification Of The Medial Part Of The Ligament Resulting In A Notch With The Minimal Diameter Along The Superior Border Of The Scapula. (6%).Type VI: The Ligament Was Completely Ossified; Resulting In A Bony Foramen Of Variable Size Located Just Inferomedial To The Base Of The Coracoid Process (4%). On The Other Hand, Following Examination Of 423 Scapulae, Natsis Et Al [2] Proposed A Classification: Type I – Without A Discrete Notch, Type II – A Notch With The Longest Transverse Diameter, Type III – A Notch With The Longest Vertical Diameter, Type IV – A Bony Foramen Type V – A Notch And A Foramen. The Third Classification Was Given By Ticker Et Al [7], He Classified The Suprascapular Notch According To Its Shape, Into Two Types, Namely 'U' And 'V' Types. The Degree Of Ossification Of The Suprascapular Ligament Was Evaluated Separately. Iqbal Et Al [3] Also Classified The Suprascapular Notch On The Basis Of Its Shape Into U, V And J Types. The Classification Given By Rengachary [6] Was Difficult To Use When Transition Between These Types Is Being Found. The Classification Given By Natsis Et Al 2 Seems To Be Simple And Includes All The Anatomical Variations Based On The Vertical And Transverse Diameters Of The SSN. The Classification By Iqbal Et Al [3] Though Provides An Easy Method Of Distinction Of SSN Based On Its Shape (U, V, And J) Without Involving Any Measurements But Some Notches Do Not Have Any Of The Three Mentioned Shapes. As The Other Shapes Of Notch Also Observed Are Wide Notch, Shallow U And Hockey Stick Shapes Are Not Included In The Classification Given By Iqbal Et Al [3]. The Most Common Type Of Notch Reported By Rengachary [6] In American Population Was Type III (The Notch Was Symmetrical And 'U'shaped With Nearly Parallel Lateral Margins) And The Least Common Was Type IV - The Notch Was Very Small And 'V'shaped. The Other Authors Who Classified The Suprascapular Notch On The Basis Of Rengachary's Classification Were Sinkeet In Kenyan [5], Muralidhar Et Al [13] And Kanhan Et Al [14] In Indians Also Found The Most Common Type Of Notch As Type III (Table 1). The Least Common Type Reported Most Of Them Was Type VI Except Kanan Et Al [14] (IV And V). The Second Type Of Classification Used By Various Authors Was By Natsis Et Al. [2] Natsis Et Al [2] In The Greek Found An Equal Incidence Of Type II (A Notch That Was Longest In Its Transverse Diameter) And Type III(A Notch That Was Longest In Its Vertical Diameter). The Least Common Type Of Notch Reported By Natsis Et Al [2] Was Type V .Based On The Classification Given By Natsis Et Al [2], Wang Et Al [4] In The Chinese, Soni Et Al [15] In The Indian And Mahdy A [16] In The Egyptian Found Type II Notch As The Most Common Type Of Notch And Type V As The Least Common Type. The Third Classification Where The Suprascapular Notch Was Classified On The Basis Of Shape According To The Classification Given By Ticker Et Al [7] And Iqbal Et Al [3].The Most Common Type Of Notch Observed By Ticker Et Al [7], Soni G Et Al [15], Muralidhar Et Al [13] And Sutaria Et Al [17] Was U Shaped Notch (In Indians), Whereas In Kenyans Hockey Stick Shaped And In Pakistanis J Shaped Notch Was Found To Be Most Common.Therefore It Is Needed That Morphometric Studies Wherein Are Performed Wherein Various Dimensions Of SSN As Well As Its Area Is Measured. These Studies Need To Be Complemented By Cadaveric Studies So As To Determine The Effect Of Variations In Attachment Of Superior Transverse Ligament On Cross Sectional Area Of Suprascapular Canal Thus Formed.

V. CONCLUSION

The results of this study indicated that Type III notch (U shape) was found to be the most prevalent type in comparison to previous studies.. A correlation between laterality and notch depth was found, with the depth of the right notch being significantly deeper. Results from this study show that research into this area of classification should be further investigated including a larger sample size for better external validity. The characteristics of the patient (gender, age and dimensions of the scapula) are not related to the characteristics of the suprascapular notch (dimensions and Type). Our findings demonstrated that entrapment syndrome is more likely to be associated with a Type VI as notchis converted to foramen.The classification given by Natsis et al includes all anatomical variations of the suprascapular notch, is based on vertical and transverse diameters of the notch, is simple and therefore seems to be the best to classify the types of SSN. Its advisable to undertake cadaveric studies so as to determine the effect of variations in attachment of superior transverse ligament on cross sectional area of of Suprascapular canal thus formed.Suprascapular nerve entrapment is an unusual condition causing pain and functional loss in the shoulder.High clinical awareness, imaging studies and electrodiagnostic examination can give confirmation about the presence of suprascapular neuropathy.The purpose of this article is to describe the anatomy of the suprascapular nerve, to define the pathophysiology of suprascapular neuropathy and to present methodically the current diagnostic and treatment strategies.The great range of morphological variation demonstrated by structures in the area of the suprascapular notch has been examined during studies on the pathogenesis of suprascapular nerve entrapment syndrome. An awareness of the variation of the structures in the suprascapular notch region, particularly the mutual relations between vessels and the suprascapular nerve, is very important because surgical approaches must be carried out with caution to avoid damage during surgery of the suprascapular nerve or bleeding from the suprascapular vessels above and below the ligament.

REFERENCES

[1] **Schilf E.** Unilateral paralysis of the suprascapular nerve. Nervenarzt. 1952;23(8):306–307. [PubMed]

[2] **Kopell H.P., Thompson W.A.** Pain and the frozen shoulder. Surg. Gynecol. Obstet. 1959;109(1):92–96.[PubMed]

[3] **Sandow M.J., Ilic J.** Suprascapular nerve rotator cuff compression syndrome in volleyball players. J. Shoulder Elbow Surg. 1998;7(5):516–521. doi: 10.1016/S1058-2746(98)90205-1. [PubMed] [Cross Ref]

[4] **Ferretti A., Cerullo G., Russo G.** Suprascapular neuropathy in volleyball players. J. Bone Jt. Surg. - Ser. A. 1987;69(2):260–263. [PubMed]

[5] **Witvrouw E., Cools A., Lysens R., Cambier D., Vanderstraeten G., Victor J., Sneyers C., Walravens M.** Suprascapular neuropathy in volleyball players. Br. J. Sports Med. 2000;34(3):174–180. doi: 10.1136/bjsm.34.3.174. [PMC free article] [PubMed] [Cross Ref

[6] **Kopell HP, Thompson WA.** Pain and frozen shoulder. Surg Gynecol Obstet 1959;109:92-96.

[7] **Natsis K, Totlis T, Tsikaras P, Appell HJ, Skandalakis K.** Proposal for classification of the suprascapular notch: a study on 423 dried scapulas. Clin. Anat. 2007;20:135-139.

[8] **Iqbal K, Iqbal R, Khan SG.** Anatomical variations in shape of suprascapular notch of scapula. J. Morphol. Sci. 2010;27:1-2.

[9] **Wang HJ, Chen C, Wu LP, Pan CQ, Zhang WJ, Li YK.** Variable Morphology of the Suprascapular Notch: An investigation and Quantitative Measurements in Chinese Population. Clin. Anat. 2011;24:47-55.

[10] **Sinkeet SR, Awori KO, Odula PO, Ogeng'o JA, Mwachaka PM.** The Suprascapular notch: its Morphology and distance from the glenoid cavity in a Kenyan population. Folia Morphol. 2010;69:241-245.

[11] **Rengachary SS, Neff JP, Singer PA, Brackett CF**. Suprascapular nerve entrapment neuropathy: A clinical, Abdelnour, H. Prevalence and pattern of injuries among players at the university of the Western Cape volleyball club. MSc. Thesis. Cape Town, University of the Western Cape, 2008. Available from: http://hdl.handle.net/11394/ 3167 anatomical and comparative study. Part 1: Clinical study. Neurosurg. 1979;5:441-6.

[12] **Usha Kannan, N.S. Khannan, J. Anbalagan, Sudha Rao:** Morphological study of suprascapular notch in Indian dry scapulae with specific reference to the incidence of completely ossified superior transeverse scapular ligament. J Clin Diagn Res. 2014 March;8(3):7-10. [15].

[13] **Soni G, Malik VS, Shukla L, Chabbra S, Gaur N** Morphometric analysis of the suprascapular notch. Internet J Biol Anthropol 2012;5:1. [16].

[14] **Mahdy AA, Shehab AA** Morphometric variations of the suprascapular notch as a potential cause of neuropathy: anatomical study. J Am Sci 2013;9:189–197.

[15] **Sutaria LK, Nayak TV, Patel SV, Jadav HR, Pensi CA** Morphology and morphometric analysis of suprascapular notch. Int J Biomed Advance Res 2013;4:35–39.

[16] **Albino P, Carbone S, Candela V, Arceri V, Vestri AR, Gumina S** Morphometry of the suprascapular notch: correlation with scapular dimensions and clinical relevance. BMC Musculoskeletal Disorders,2013;14:172.

[17] **Polguj M, Jêdrzejewski K, Podgórski M, Topol M.** Morphometric study of the suprascapular notch: proposal of classification. Surg Radiol Anat. 2011 Nov;33(9):781-7.

[18] **Zahid A, Khan Mw, Khan B.** Ossified superior transverse scapular ligament, A morphological study on dried Pakistani scapulae. Biomedica. 2014;30:1-4.

*****

Corresponding author :

Dr. Shabana Sultana *

Tutor, Department of Anatomy, Apollo Institute of Medical Sciences and Research, Hyderabad, Telangana, India.

Email : shabanasultana.m[at] gmail.com